

# EFFICACY OF ULTRASOUND IN DETECTING RENAL CALCULI KEEPING NON-ENHANCED COMPUTED TOMOGRAPHY AS A REFERENCE STANDARD

Sybil Rose<sup>1,2</sup>, Talat Hussain Toor<sup>1</sup>, Asma Aslam<sup>1</sup>, Esha Hashmi<sup>1</sup>, Ambreen Sadaf<sup>1</sup>, Rana Muhammad Athar<sup>1</sup>

1. Superior University, Lahore, Punjab, Pakistan.

## ABSTRACT

Renal calculi is an emergency condition and must be diagnosed to evaluate the presence and location of renal calculi as early as possible. To evaluate the efficacy of ultrasound in detecting renal calculi keeping non-enhanced computed tomography as a reference standard. An analytical cross-sectional study was performed at Gurki Trust Hospital, Lahore. All patients with suspicion of renal calculi were included, while patients with polycystic disease, dialysis, ureteric stricture, and those who refused to give informed consent were excluded. Ultrasound was performed bilaterally, focusing on ureters. 16 slice Computer tomography scanner was used to perform computer tomography scan. Out of 121 patients, 46 (38%) females and 75 (62%) males were examined, on ultrasound, 74 (61.2%) patients had no evidence of renal calculi, while 47 (38.8%) were reported with presence of renal calculi, on contrary, CT scan was performed on same patients showing, 108 (89.3%) with renal calculi and 13 (10.7%) with no evidence of renal calculi. The transabdominal ultrasonography showed an accuracy 83.47%, sensitivity 74.6%, specificity 69.6%, PPV (positive predictive value) 97.8% and NPV (negative predictive value) 37.9%. Efficacy of ultrasound is comparable to CT, therefore can be considered as an alternative method when CT scan is unavailable or cannot be performed, i.e.; pregnant female. Moreover, ultrasound is cost effective, easily available modality and without radiation exposure, hence making it more appropriate for both initial and follow-up evaluations.

**Keywords:** Non-enhanced Computed Tomography, Renal Calculi, Radiation, Ultrasound.

## INTRODUCTION

Renal calculi are a serious medical condition which affects males 12% and females 7% globally, risk is increased due to family history of renal calculi<sup>1</sup>. In Pakistan, renal calculi are the 6th most frequently treated disease<sup>2</sup>. Up to 6% of females are predicted to develop single or multiple episodes of renal calculi during their life and 50% chances of recurrence between the age range of 35 – 45<sup>3</sup>. According to American guideline, normal function of kidneys is important for renin-angiotensin-aldosterone system<sup>4</sup>. Renal calculi cause flank pain, dysuria, hematuria resulting from urinary stasis, causing obstruction, low urine volume as result of dehydration, high nutritional factors such as calcium oxalate and sodium intake, urinary tract infections (UTI), systemic acidosis, drugs, and less commonly genetic factors such as cystinuria, affecting 1 out of 11 people at some point in their lives, males are more prevalent as compared to females 2:1<sup>5</sup>. Fever, UTI, chills, nausea and vomiting are also reported in patients with renal calculi, if not treated complications can occur, if calculi are impacted in ureter, disrupting the urine flow resulting in severe UTI or chronic kidney disease (CKD)<sup>6</sup>. Ultrasound is an initial modality used to evaluate renal calculi and can also be used as follow up scans, sensitivity, and specificity of ultrasound for the evaluation of renal calculi can vary depending on the patient lifestyle, size of calculus and technique used to scan by the operator, with the addition of an x-ray of kidney, ureter, and bladder (KUB) abdomen, ultrasonography becomes more sensitive for the detection of renal calculi<sup>7</sup>. CT KUB is considered as a reference standard for the detection of renal calculi, however, it has several limitations, such as a lack of spatial resolution, which might depict subtle calculi and stone pieces incorrectly<sup>8</sup>. If CT scan is performed multiple times for follow up studies it contributes in exposure radiation doses, although, Low dose protocols are practiced to reduce the biological effects due to radiation<sup>9</sup>. The use of CT KUB for the detection of renal calculi is still relatively new in Pakistan; because of unavailability, lack of knowledge regarding scanning techniques and is expensive comparable to ultrasound<sup>10</sup>. The aim of our study was to evaluate the diagnostic accuracy of ultrasonography for the detection of renal calculi to avoid radiation risk, in infants and pregnant females.

## MATERIALS AND METHODOLOGY

An analytical cross-sectional study was performed using non-probability convenient technique at Gurki Trust Hospital, Lahore from 2018 to 2022, after the approval of Institutional Review Board (IRB), at Superior University, Lahore. All patients with suspicion of renal calculi were included, while patients with polycystic disease, dialysis, ureteric stricture, and those who refused to give informed consent were excluded. Ultrasound was performed bilaterally, focusing on ureters. 16 slice CT scanner was used to perform CT scan.

## RESULTS

Out of 121 patients, 46 (38%) females and 75 (62%) males were examined. Presenting with flank pain, oliguria, hematuria, and fever. On ultrasound, 74 (61.2%) patients had no evidence of renal calculi, while 47 (38.8%) were reported with presence of renal calculi, on contrary, CT scan was performed on same patients showing, 108 (89.3%) with renal calculi and 13 (10.7%) with no evidence of renal calculi. The transabdominal ultrasonography showed an accuracy 83.47%, sensitivity 74.6%, specificity 69.6%, PPV 97.8% and NPV 37.9%.

## DISCUSSION

The present study included, 121 patients, female 46 (38%), while the male 75 (62%). On ultrasound, 47 (38.8%) patients were detected with renal calculi, while 74 (61.2%) patients had no evidence of renal calculi. On CT scan, it was observed that out of 121, 108 (89.3%) were positive for the presence of renal calculi, whilst 13 (10.7%) were negative for stone detection. The transabdominal ultrasonography demonstrated a sensitivity 74.6%, specificity 69.6%, positive predictive value (PPV) 97.8%, negative predictive value (NPV) 37.9%, and an overall accuracy 83.47%.

Transabdominal sonography can detect renal calculi, proximal vesicoureteral junction, and urine bladder, as well as the obstructions size and intensity, intestinal gas shadows obscure the ureter, reducing vision, ultrasound findings combined with abdominal X-rays can improve diagnosis accuracy, although other emerging methods like contrast medium and transrectal or transvaginal sonography may increase diagnosis accuracy<sup>11</sup>. According to our study, transabdominal ultrasonography is a reliable renal calculi diagnosis method, especially for pregnant women and children. Modern methods and equipment,

together with intravenous contrast material, may improve ultrasonography renal calculi detection capabilities<sup>12</sup>. Some radiologists choose ultrasound for renal stone assessment due to its non-invasiveness, cost, and lack of radiation<sup>13</sup>. In 2019, Altaf et al., conducted a systematic review in a sample of 250 patients who reported with lumbar discomfort and concluded that computed tomography (CT) is the most effective and dependable technology for detecting renal calculi. However, they also observed that ultrasound can be a preferable alternative to CT in order to reduce the radiation exposure dose. The diagnostic use of ultrasound in accurately detecting urethral stones is limited. In order to mitigate the potential variability introduced by operator dependence, it is customary for patients exhibiting symptoms of renal colic to undergo a plain CT (KUB) examination<sup>14</sup>.

Maryam et al. (2022) observed comparable results, with a sensitivity 65%, specificity 72.09%, positive predictive value (PPV) 79.66%, negative predictive value (NPV) 55.36 %, and diagnostic accuracy 67.83%<sup>15</sup>.

Aqsa Rao et al., (2021) showed in a total of 121 patients, 82 (67.8%) females, whilst 39 (32.2%) males. On ultrasound, 61 (50.4%) were found to have ureteric calculi, whilst the remaining 60 (49.6%) did not show any presence of ureteric calculi. On CT scan, it was seen that out of the total number of patients, 110 (90.9%) were found to have ureteric calculi, whereas 11 (9.1%) did not show any presence of ureteric calculi. The statistical analysis indicated that this difference was not statistically significant, as the p-value >0.05. The transabdominal ultrasonography had a sensitivity 58.62%, specificity 56.76%, positive predictive value (PPV) 51.52%, negative predictive value (NPV) 63.64%, and diagnostic accuracy 57.68%<sup>16</sup>.

In a study conducted by Dalla Palma et al., (2001) a total of 120 patients presenting with renal colic were assessed using ultrasound (US) and plain radiographs, revealed a sensitivity 95% but a specificity 67%. In the study, the United States (US) cases were categorized as positive for ureteric colic if they exhibited the presence of calculi or hydronephrosis. In the present investigation, only instances where there was a clear manifestation of ureteral calculi were categorized as positive, and our findings indicate a notable specificity 95%. In the present investigation, computed tomography (CT) and ultrasound imaging techniques exhibited comparable levels of sensitivity in the detection of ureteral calculi<sup>17</sup>.

In our perspective, abdominal ultrasonography exhibits a multitude of advantages as a diagnostic modality for identifying ureteric calculi, particularly in the context of pregnant females and newborns, as well as for subsequent monitoring purposes. The utilization of novel methodologies and advanced instrumentation, in conjunction with the expertise of sonographers, has the potential to enhance the diagnostic accuracy of ultrasonography in detecting ureteric calculi.

## CONCLUSION

In the study, out of 121 patients, 46 (38%) were females and 75 (62%) were males. The patients were examined for the presenting symptoms of flank pain, oliguria, hematuria, and fever.

On ultrasound, 74 (61.2%) patients showed no evidence of renal calculi, while 47 (38.8%) were reported to have renal calculi. However, CT scans performed on the same patients revealed 108 (89.3%) with renal calculi and 13 (10.7%) with no evidence of renal calculi.

Transabdominal ultrasonography demonstrated an accuracy of 83.47%, sensitivity of 74.6%, specificity of 69.6%, positive predictive value (PPV) of 97.8%, and negative predictive value (NPV) of 37.9%.

Efficacy of ultrasound is comparable to CT, therefore can be considered as an alternative method when CT scan is unavailable or cannot be performed, i.e.; pregnant female. Moreover, ultrasound is cost effective, easily available modality and without radiation exposure, hence making it more appropriate for both initial and follow-up evaluations.

## Recommendation:

More similar studies needed for the pregnant and small children.

## CONFLICT OF INTEREST

There was no conflict of interest.

## REFERENCE

1. Sofia NH, Walter TM, Sanatorium T. Prevalence and risk factors of kidney stone. *Global Journal For Research Analysis*. 2016 Mar 5;5(3):183-7.
2. Ahmad S, Ansari TM, Shad MA. PREVALENCE OF RENAL CALCULI: TYPE, AGE AND GENDER SPECIFIC IN SOUTHERN PUNJAB, PAKISTAN. *The Professional Medical Journal*. 2016;23(04):389-95.
3. Li Y, Bayne D, Wiener S, Ahn J, Stoller M, Chi T. Stone formation in patients less than 20 years of age is associated with higher rates of stone recurrence: results from the Registry for Stones of the Kidney and Ureter (ReSKU). *Journal of pediatric urology*. 2020 Jun 1;16(3):373-e1.
4. Asif HS, Naeem MW, Rose S, Hussain M, Iqbal R, Irfan M, et al. Ultrasonographic Correlation of Cortical Thickness and Echogenicity Among Patients Suffering From Chronic Renal Failure [Internet]. *Social Science Research Network*. Rochester, NY; 2019 [cited 2023 Sep 21].
5. Asif S, Khalil S, Rose S, Ahmed M, Shams RMAA, Sadaf A. Sonographic Evaluation of Chronic Kidney Disease Correlating with Serum Creatinine Level. *Journal of Health, Medicine and Nursing* [Internet]. 2021 [cited 2023 Sep 21];90(0):20.
6. Johnson JR, Russo TA. Acute pyelonephritis in adults. *New England Journal of Medicine*. 2018 Jan 4;378(1):48-59.
7. Ganesan V, De S, Greene D, Torricelli FC, Monga M. Accuracy of ultrasonography for renal stone detection and size determination: is it good enough for management decisions?. *BJU international*. 2017 Mar;119(3):464-9.
8. Brisbane W, Bailey MR, Sorensen MD. An overview of kidney stone imaging techniques. *Nature Reviews Urology*. 2016 Nov;13(11):654-62.
9. Cao CF, Ma KL, Shan H, Liu TF, Zhao SQ, Wan Y, Wang HQ. CT scans and cancer risks: A systematic review and dose-response meta-analysis. *BMC cancer*. 2022 Nov 30;22(1):1238.
10. Alahmadi AE, Aljuhani FM, Alshoabi SA, Aloufi KM, Alsharif WM, Alamri AM. The gap between ultrasonography and computed tomography in measuring the size of urinary calculi. *Journal of Family Medicine and Primary Care*. 2020 Sep;9(9):4925.
11. Ahmed F, Askarpour MR, Eslahi A, Nikbakht HA, Jafari SH, Hassanpour A, Makarem A, Salama H, Ayoub A. The role of ultrasonography in detecting urinary tract calculi compared to CT scan. *Research and reports in urology*. 2018 Nov 15:199-203.
12. Fazel M, Gubari MI, Youseffard M, Hosseini M. Ultrasonography in detection of renal calculi in children; a systematic review and meta-analysis. *Archives of Academic Emergency Medicine*. 2019;7(1).
13. McCarthy CJ, Baliyan V, Kordbacheh H, Sajjad Z, Sahani D, Kambadakone A. Radiology of renal stone disease. *International Journal of Surgery*. 2016 Dec 1;36:638-46.

14. Altaf N, Kamran A, Naseem B, Iqbal M, Asif R, Farooq S, Javed S, Yousaf SM. Diagnostic accuracy of ultrasonography versus computed tomography for ureteric calculi among the adult patients visiting Mayo Hospital Lahore. J Health Med Sci. 2019;2:68-74.

15. Ata T, Maryam S, Zakir M, Qayyum SA, Farooq SM, Fatima ME, Iqbal AM, Gilani SA, Shafiq MU, Tariq A, Khan H. Different Diagnostic Findings in patients with Gross Hematuria on Computed Tomography Urography. Pakistan Journal of Medical & Health Sciences. 2022 Apr 30;16(04):177-.

16. Rao A, Toor A, Fatima M, Noor J, Sabir R, Rose S, et al. Diagnostic Accuracy of Ultrasound for the Evaluation of Ureteric Calculi Taking Non-enhanced Computed Tomography as a Gold Standard. Journal of Health, Medicine and Nursing [Internet]. 2021 [cited 2023 Sep 21];90(0):15.

17. Dalla Palma L, Pozzi-Mucelli R, Stacul F. Present-day imaging of patients with renal colic. European radiology. 2001 Jan;11:4-17.

IMAGES

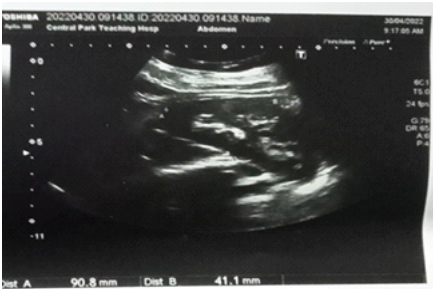

Figure 1: Ultrasound of left kidney showing moderate hydronephrosis

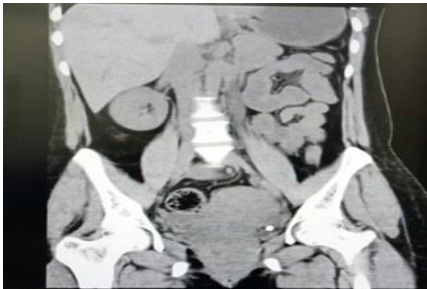


Figure 2: CT scan showing calculus in left Vesicoureteric Junction (VUJ).

Address for Correspondence:

✉ Lecturer Superior University, Lahore, Punjab, Pakistan.  
@ sybil.rose@superior.edu.pk  
📞 0304-7757301

Received: March 19, 2024 , Revised: June 13, 2024, Accepted: Nov 24, 2024

Contribution of Authors:	
CONTRIBUTION	AUTHOR ABBREVIATION
Conception & Planning of the Research	SR, THT
Active Participation in Methodology	AA, SR, EH, RMA
Interpretation Analysis & Discussion	SR, EH, AS, RMA

CONFLICT OF INTEREST
None Declared
GRANT SUPPORT AND FINANCIAL DISCLOSURE
NIL
Authors agree to be accountable for all aspects of the work in ensuring that questions related to the accuracy or integrity of any part of the work are appropriately investigated and resolved.